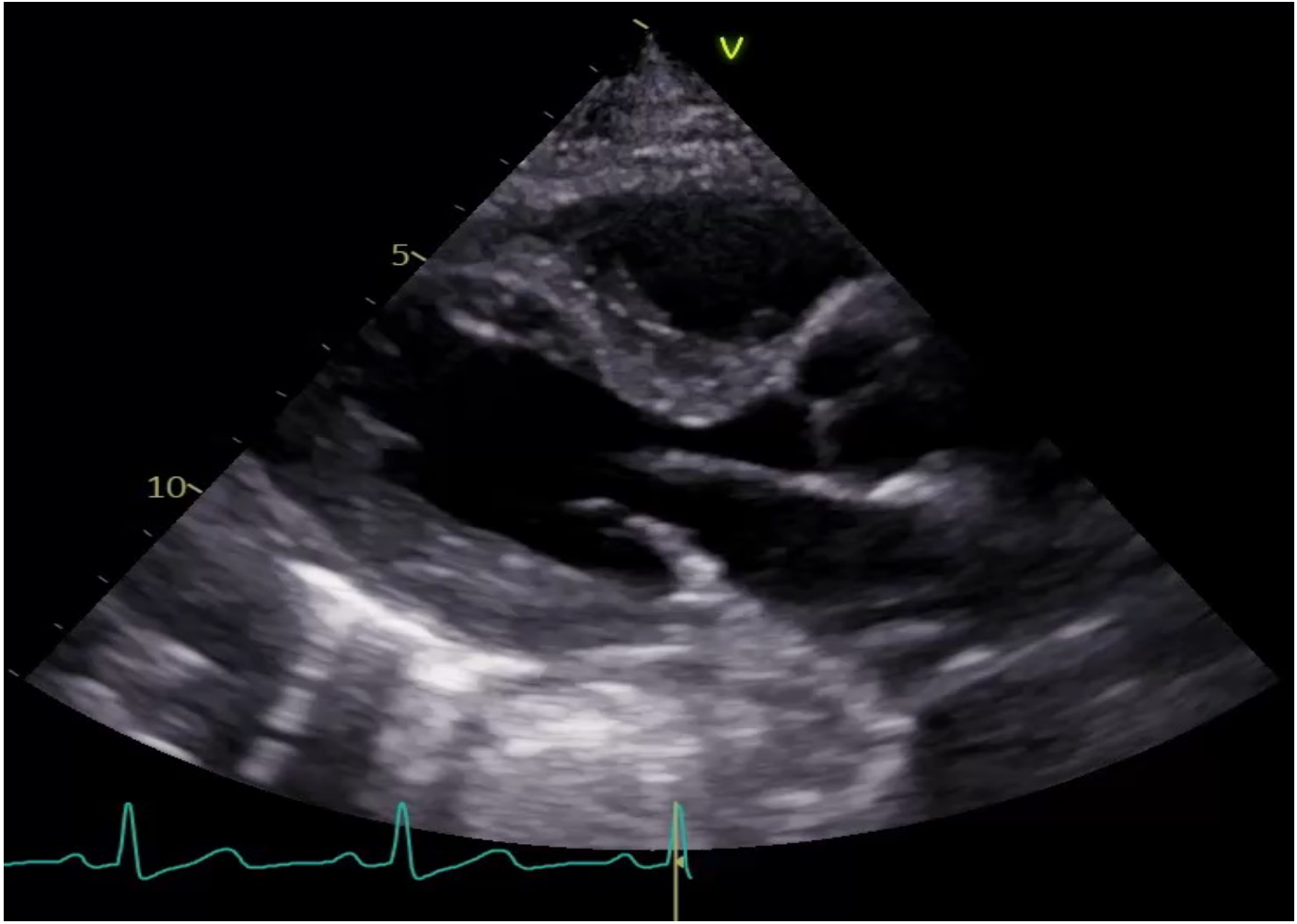


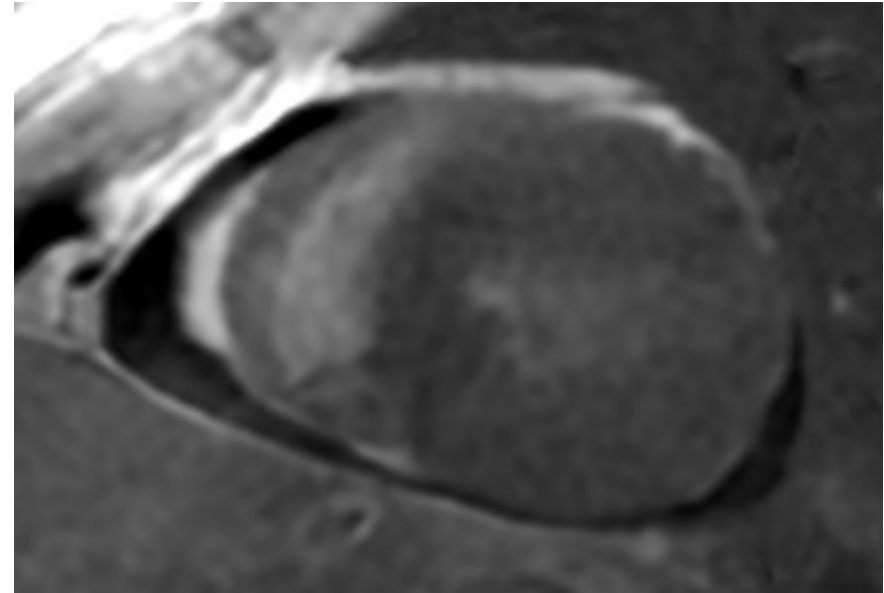
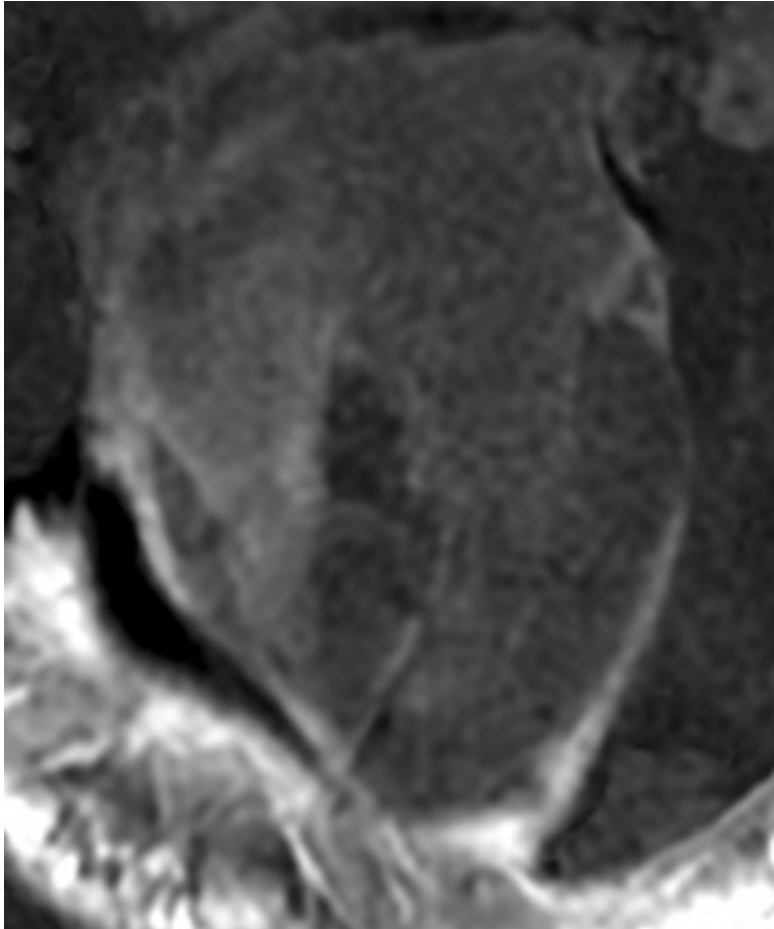


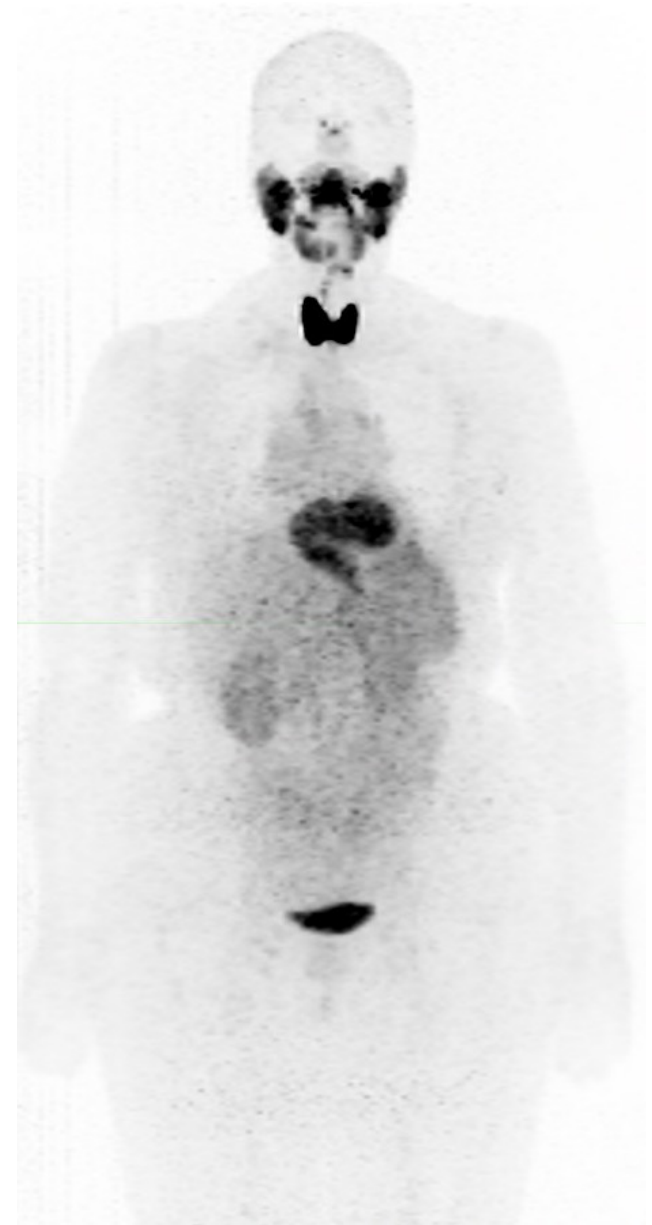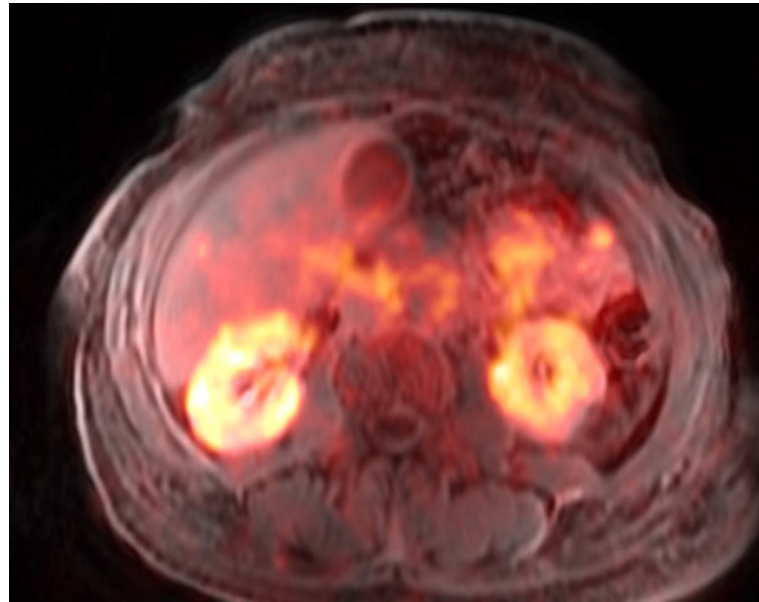
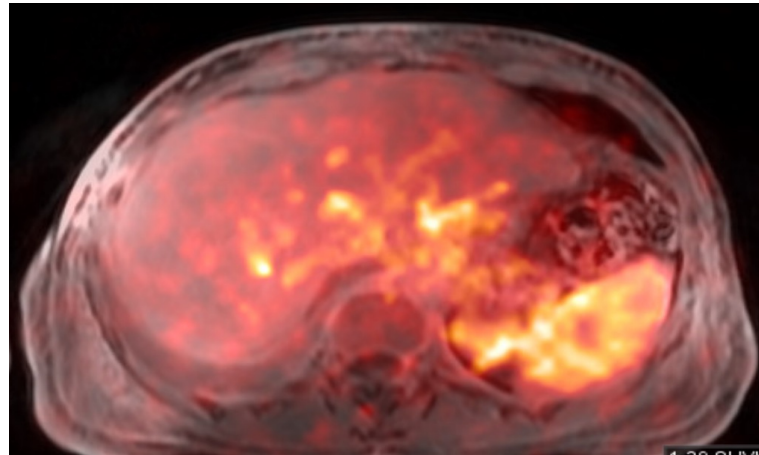
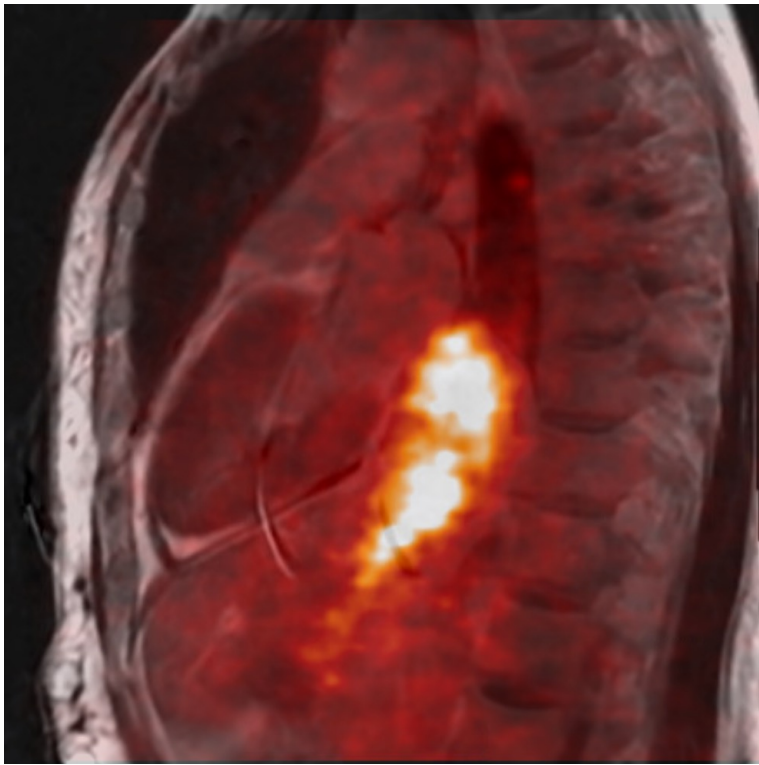
28th Annual Scientific Session and Exhibition
of the American Society of Nuclear Cardiology

^{124}I -evuzamitide PET/MR Unveils Hypertrophic Cardiomyopathy in a Patient with Renal AL Amyloidosis

Jessica Cardin, Derrick Gillan, Adam Brown,
Nadine Mallak, Eva Medvedova, Ahmad Masri







¹²⁴I-*evuzamitide* PET/MR Unveils Hypertrophic Cardiomyopathy in a Patient with Renal AL Amyloidosis

Jessica Cardin, Derrick Gillan, Adam Brown, Nadine Mallak, Eva Medvedova, Ahmad Masri

Patient Presentation: 69-year-old female who presented with dyspnea and found to have pleural effusions requiring thoracoscopic surgery and pleurodesis. Patient represented with worsening symptoms and she was found to have nephrotic-range proteinuria. No history of hypertension, cardiac or renal disease.

Diagnostic work up: Nephrotic-range proteinuria (12 g/day), lambda light chain was 270 mg/l, and kappa light chain was 44 mg/l. Lung biopsy was sent for Congo red which was positive and mass spectrometry showed AL amyloid deposits. An echocardiogram (Figure) revealed moderate left ventricular hypertrophy, normal systolic function and left ventricular outflow tract obstruction. NT-proBNP was 3,080 pg/dl and high sensitivity troponin I (hsTnI) was 12 ng/l. Patients was recommended to start standard of care chemotherapy and consider enrollment into a clinical trial for cardiac amyloidosis.

Follow up: Clinically, patient was doing well from a cardiac perspective which was discordant with her moderate LVH and high NT-proBNP. hsTnI was lower than expected. Enrollment into the ongoing ¹²⁴I-*evuzamitide* PET/MR study was recommended (NCT05758493), which showed renal, liver and spleen tracer uptake, without cardiac uptake. In addition, CMR showed no LGE and mildly elevated ECV at 39% resulting in a working diagnosis of renal AL amyloidosis and obstructive hypertrophic cardiomyopathy (HCM) without cardiac amyloidosis.

Teaching points: left ventricular hypertrophy can result from a multitude of conditions even in the setting systemic amyloidosis. While hypertensive cardiomyopathy is a more commonly encountered cause of LVH, the example above shows the significance of defining each organ involvement in systemic amyloidosis, given the personal and family implications of HCM diagnosis, as well as avoiding enrollment into cardiac amyloidosis trials. While we have not biopsied the heart, the clinical presentation, the severity of LVH, and the lack of LGE make cardiac amyloidosis highly unlikely.

Figure. Multimodality imaging including (A) parasternal long axis view on echocardiography showing systolic anterior motion of the mitral valve with left ventricular outflow tract obstruction and mitral regurgitation (B) Late gadolinium enhancement imaging on CMR showing no LGE (C) ^{124}I -evuzamitide PET/MR showing no cardiac tracer uptake with physiologic tracer excretion in a hiatal hernia and (D) ^{124}I -evuzamitide PET/MR showing bilateral renal uptake.

